

## Jejunal Diverticulosis: Review of Literature and Case Report

Mishra Anurag\*, Dinesh Anant\*\*, Neogi Shushanto\*\*\*, Gautam Devyani\*\*

\*Assistant professor, \*\*Resident, \*\*\* Professor, Department of General Surgery, Maulana Azad Medical College, New Delhi

### Abstract

In contrary to diverticula at other sites, jejunal diverticulosis is very rarely encountered in clinical practice and thus is often missed. Diagnosis is often incidental in imaging or during surgery. The disease is interesting as in varied presentations Here we present our experience with one such case and a review of literature of this rare entity.

**Keywords:** diverticulum; peritonitis; intestinal perforation

### Introduction

One meaning of diverticula is a wayside house of the ill-famed; certainly these wayside houses give rise to many pathological conditions. Diverticula can occur from the stomach to the rectosigmoid. Diverticula of small intestine are rare. Jejunal diverticula are the rarest of all small bowel diverticula and were first described by Somerling in 1794<sup>1</sup> and by Sir Astley Cooper in 1807<sup>2</sup>. An incidence of 0.5%-2.3% of small bowel contrast studies and 0.3%-4.5% of autopsies has been reported in the literature<sup>3</sup>. We here present a case of jejunal diverticulosis with perforation.

### Case History

A patient 65 year old male, a known case of dementia with seizure disorder, diagnosed as BINSWANGER DISEASE, on Tab Phenytoin 300mg once daily was referred to surgical emergency with complaints of sudden onset pain in abdomen for 2 days. Pain was severe in intensity and aggravated on moving. It was associated with vomiting and obstipation for 2 days. Patient had no documented history of hypertension, diabetes mellitus and tuberculosis. Patient had no history of any previous surgeries or trauma.

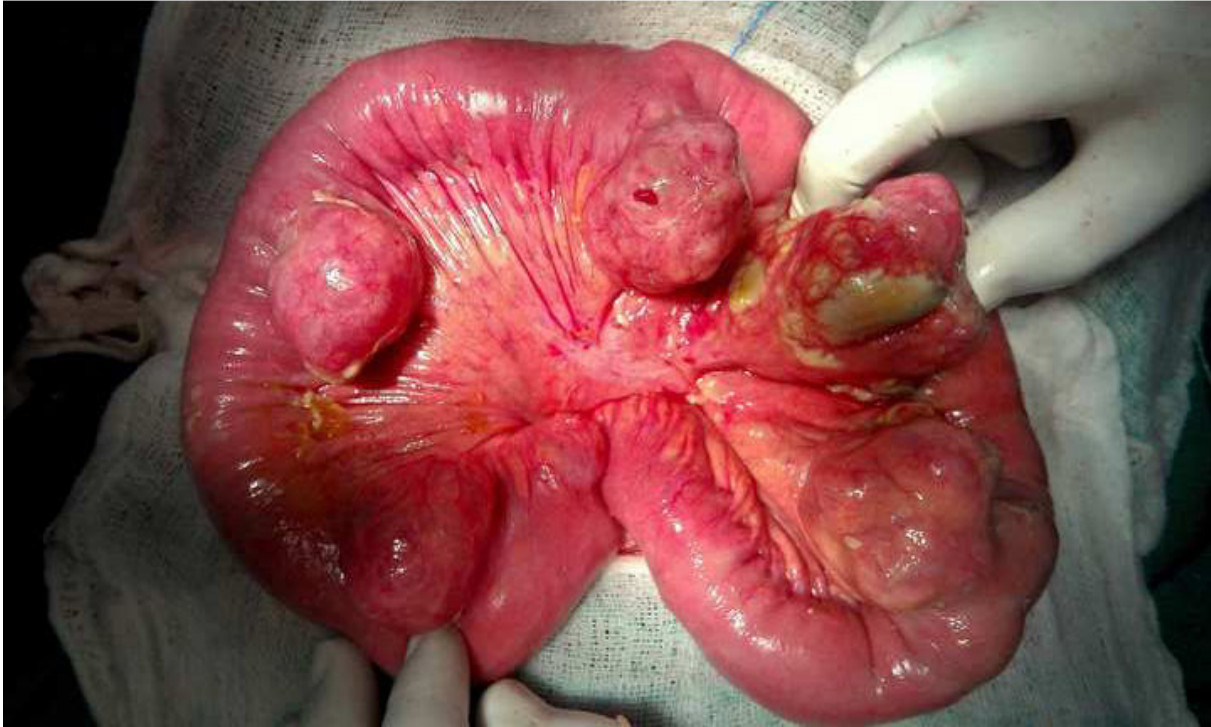
On examination at presentation, patient was conscious and oriented, responding to verbal commands with GCS 15/15. Patient had tachycardia with hypotension. On abdominal examination, generalized distention and rigidity was seen. Rebound tenderness was present all over the abdomen. He was diagnosed for perforation peritonitis after radiological confirmation pnuemoperitoneum.

Patient was taken up for urgent exploratory laparotomy after adequate optimization and resuscitation. Per-operatively, pyo-pnuemoperitoneum was present. On exploring bowel, multiple jejunal diverticula were seen at the mesenteric border with multiple perforations with thinning of diverticular wall. The involved jejunal segment (roughly 30cms) was resected (Fig 1) and jejuno-ileal anastomosis (end to end) was done after thorough peritoneal lavage with warm saline.

---

**Corresponding Author:** Dr Anurag Mishra, Assistant professor, Department of General Surgery, Maulana Azad Medical College, New Delhi 110002

E-mail: anurag.alok@gmail.com



**Fig. 1: Photograph of resected specimen showing multiple diverticulae with perforation**

Bilateral flank drains were placed and abdomen was closed in layers. Postoperatively, patient was transferred to ICU for ventilator support and further management.

### Review and Discussion

Jejunal diverticulosis is extremely rare. Geroulakos G, in his study carried out over a period of ten years, observed only 13 cases out of which 7 patients had perforation of the diverticulum while 3 had inflammation and 2 had haemorrhage. Shahid Majeed<sup>4</sup> from Sargodha and Telgote AV<sup>5</sup> from Bombay reported 1 and 2 cases of perforated jejunal diverticula in 2004 and 2007 respectively

Jejunal diverticula can be single or multiple. These false diverticula are acquired outpouchings of mucosa commonly found on the mesenteric border of the jejunum. Jejunal diverticula share similarities with colonic diverticula in that the mucosal herniations occur through gaps in the muscle layers along pathways of the visceral vessels. They can be of congenital or acquired type. In the congenital diverticula all 3 coats of bowel are present while in acquired diverticula muscular layer is absent. The sizes of these diverticula vary between a few millimetres to greater than ten centimetres. Of these

diverticula, 35% are associated with colonic diverticula, 26% with duodenal diverticula and 2% with oesophageal diverticula. <sup>6</sup> In rest of cases jejunum is the only site of diverticulosis.

Small bowel diverticula are frequently encountered in the elderly and have a slight male predominance. Their presentation is variable from asymptomatic to chronic abdominal symptoms like pain, flatulence, and borborygmi. It may also produce malabsorption syndrome, or may present in emergency with different acute pathologies like perforation, haemorrhage, obstruction, enterolith formation and inflammation. Their relative clinical rarity and varied presentation may make diagnosis both delayed and difficult. The discovery of jejunal diverticula may be incidental in imaging studies or may be found at laparotomy.

Haemorrhage from jejunal diverticula predominantly presents as lower gastrointestinal bleeding although cases of haematemesis have been reported. This bleeding may be acute or chronic with iron deficiency anaemia. Gastrointestinal haemorrhage from the jejunum has a similar aetiology to that seen in the large bowel diverticula in that the diverticulum erodes through a perforating artery. The routine techniques such as gastroduodenoscopy or colonoscopy are unable to visualise the jejunum. Hence, enteroscopies and

computed tomography scans are used as they are able to visualise such regions and thus establish the diagnosis. The most sensitive imaging studies are technetium red cell-tagged scan and/or mesenteric angiogram. The technique also has the advantage of offering mesenteric embolization. Hemodynamic instability warrants emergency laparotomy, as adjunct to intense supportive therapy with the purpose of finding the precise bleeding point and ensuring definitive treatment. The preferred surgical approach to acute haemorrhage is intestinal resection of the bleeding jejunal segment with primary anastomoses.

Perforation generally presents generalized or localised peritonitis. Perforation is rare, which may be explained by the low intraluminal pressures within the small bowel. Instigating factors for perforation can be necrotizing inflammatory reaction in 82% of cases, followed by blunt trauma in 12% of cases and foreign body impaction in 6% of cases<sup>7</sup>. Computed tomography is the most useful diagnostic imaging tool in such cases. It has proved to be superior to barium studies in demonstrating the mural, serosal and mesenteric extent of disease. The management is surgical with resection of the diseased segment followed by primary jejuno-jejunal or jejuno-ileal anastomoses. Previous studies have shown that a laparoscopic approach is successful. Extensive resection should be avoided as this has the potential to lead to short bowel syndrome. Novak et al<sup>8</sup> have demonstrated a few cases where a localised perforation of jejunal diverticula could be treated non-surgically with intravenous antibiotic therapy and computed tomography-assisted percutaneous drainage of the abscess.

Acute intestinal obstruction is another complication of jejunal diverticula. Obstruction may be related to extrinsic compression from a nearby loop of jejunum containing a large diverticulum or from intussusception or may be non-mechanical such as dyskinesia. Obstruction may also be secondary to enterolith formation or gallstone migration. Enteroliths may form inside the diverticulum and consist of choleic acid, either de novo or around a bezoar. The acidic environment within diverticula is ideal for aiding the metabolism of bile salts to choleic acid, hence enterolith obstruction. There are various

diagnostic modalities which can be useful in such presentations. Abdominal radiographs may provide evidence of stones in the abdomen external to sites such as the gallbladder or renal tracts. Ultrasound examination may confirm or exclude gallstones. The diagnosis may be confirmed with either barium imaging or computed tomography scanning. Management may be either conservative or surgical. Strategies, which may be used during laparotomy, are crushing of the enteroliths and milking their fragments into the colon. If this is unsuccessful, an enterostomy can be performed proximal or distal to the site of obstruction with the enterolith removed. If these two steps are unsuccessful, resection of the involved jejunal segment may have to be considered.

Though Jejunal diverticula are rare, awareness of the wide spectrum of associated complications may be useful in preventing delay in treatment.

## References

1. Soemmering ST, Baille M. Anatomie des krankhaften Baues von einigen der wichtigsten Theile in menschlichen Korper. Berlin: Vossische Buchhandlung; 1794:1-97.
2. Cooper A. Anatomy and Surgical Treatment of Crural Umbilical Hernia. London: Edinburgh Medical and Surgical Journal; 1807:475-87
3. Wilcox RD, Shatney CH. Surgical implications of jejuna diverticula. South Med J 1988; 81: 1386-91
4. Majeed S, Saeed A. Perforated jejunal diverticulum. Pak Armed Forces Med J 2004;54(1):134-5.
5. Telgote AV; Chandak MR; Hedawoo JB. Perforated Jejunal Diverticulum-Report of Two Cases. Bombay Hospital J 2007;49:381-4.
6. Baskin RH Jr, MAYO CW. Jejunal diverticulosis; a clinical study of 87 cases. Surg Clin North Am 1952; 1185-96
7. Herrington JL Jr. Perforation of acquired diverticula of the jejunum and ileum. Analysis of reported cases. Surgery 1962; 51: 426-33
8. Novak JS, Tobias J, Barkin JS. Nonsurgical management of acute jejunal diverticulitis: a review. Am J Gastroenterol 1997; 92: 1929-31